




Retrograde intrarenal surgery: Past, present, and future

Takaaki Inoue^{1,2} , Shinsuke Okada³, Shuzo Hamamoto⁴, Masato Fujisawa²

¹Department of Urology and Stone Center, Hara Genitourinary Hospital, Kobe, Hyogo, ²Department of Urology, Kobe University, Kobe, Hyogo, ³Department of Urology, Gyotoku General Hospital, Ichikawa, Chiba, ⁴Department of Urology, Medical School, Nagoya City University Graduate School of Medical Sciences, Nagoya, Aichi, Japan

With the recent technological advancements in endourology, retrograde intrarenal surgery has become a more popular procedure for treatment of urolithiasis. Furthermore, since the introduction of new laser systems and advanced flexible ureteroscopy with miniaturized ureteroscopes, the treatment indications for retrograde intrarenal surgery have expanded to include not only larger renal stones of >2 cm but also upper urinary tract urothelial carcinoma, ureteral stricture, and idiopathic renal hematuria. Clinicians must keep up with these trends and make good use of these technologies in the rapidly changing field of endourology. Simultaneously, we must consider the risk of various complications including thermal injury due to laser use, ureteral injury caused by the ureteral access sheath, and radiation exposure during retrograde intrarenal surgery with fluoroscopic guidance. This review focuses on the past, present, and future of retrograde intrarenal surgery and provides many topics and clinical options for urologists to consider.

Keywords: Flexible ureteroscopy; Kidney stone; Laser; Retrograde intrarenal surgery

This is an Open Access article distributed under the terms of the Creative Commons Attribution Non-Commercial License (<http://creativecommons.org/licenses/by-nc/4.0>) which permits unrestricted non-commercial use, distribution, and reproduction in any medium, provided the original work is properly cited.

INTRODUCTION

Current advancements in endoscopic technology for the upper urinary tract have allowed for the diagnosis and management of kidney stones, upper urinary tract urothelial carcinoma (UTUC), ureteral stricture, renal bleeding, and other disorders. In particular, these technological developments have expanded the treatment options for upper urinary tract stones. Retrograde intrarenal surgery (RIRS), defined as the use of flexible ureteroscopes (fURSS) and effective lithotripters such as holmium:yttrium aluminium garnet (holmium:YAG) lasers for intrarenal pelvic diseases, is a useful, versatile, and minimally invasive procedure for kidney stone management. The current guideline for man-

agement of kidney stones includes RIRS as the first or second recommended procedure in all categories, even for large stones of >2 cm [1,2]. In addition, new instruments such as high-power holmium:YAG lasers, thulium fiber lasers, and single-use ureteroscopes have been introduced for greater safety, efficiency, and comfort for both patients and surgeons. However, various concerns have emerged in clinical practice, including complications, cost-effectiveness, and how to use these new devices simultaneously [3]. As technological advancements have progressed, the quality of medical care has changed. This review provides an overview of endourological procedures, RIRS for the upper urinary tract, key points of surgical techniques including required instruments, and future trends in this field.

Received: 12 November, 2020 • **Revised:** 9 December, 2020 • **Accepted:** 10 December, 2020 • **Published online:** 22 February, 2021

Corresponding Author: Takaaki Inoue  <https://orcid.org/0000-0002-6050-5452>

Department of Urology and Stone Center, Hara Genitourinary Hospital, 5-7-17 Kitanagasadori, Chuo-ku, Kobe, Hyogo 650-0012, Japan
TEL: +81-72-804-0101, FAX: +81-72-804-0131, E-mail: inouetak@harahospital.jp

Table 1. The specification of current available fURSs

| Company | fURS | Imaging system | Field of view (°) | Active deflection (up/down; °) | Length (mm) | Working channel (Fr) | Diameter (tip/shaft; Fr) |
|--------------------|-------------------|----------------|-------------------|--------------------------------|-------------|----------------------|--------------------------|
| Lumenis | Polyscope | Optical | - | 180/0 | - | 3.6 | 8.0/8.0 |
| Olympus Gyrus ACMI | DUR-8 Elite | Optical | 80 | 270/270 | 640 | 3.6 | 8.7/9.4 |
| | DUR-8 Ultra | Optical | 80 | 270/270 | 650 | 3.6 | 8.6/9.36 |
| | DUR-D | Digital | 80 | 250/250 | 650 | 3.6 | 8.7/9.3 |
| Olympus | URF P5 | Optical | 90 | 275/180 | 670 | 3.6 | 5.3/8.4 |
| | URF P6 | Optical | 90 | 275/275 | 670 | 3.6 | 4.9/7.95 |
| | URF P7 | Optical | 90 | 275/275 | 670 | 3.6 | 4.9/7.95 |
| | URF V2 | Digital | 80 | 275/275 | 670 | 3.6 | 8.5/9.9 |
| Storz | FLEX-X2s | Optical | 110 | 270/270 | 675 | 3.6 | 7.5/8.4 |
| | FLEX-Xc | Digital | 90 | 270/270 | 700 | 3.6 | 8.5/8.5 |
| Wolf | Cobra-M | Optical | 85 | 270/270 | 680 | 3.3 (dual) | 6.0/9.9 |
| | Viper | Optical | 86 | 270/270 | 680 | 3.6 | 6.0/8.8 |
| | Boa-vision | Digital | - | 270/270 | - | 3.6 | 8.7/- |
| | Cobra-vision | Digital | - | 270/270 | - | 3.6/2.4 | 9.9/- |
| Stryker | Flex Vision U-500 | Optical | 90 | 275/275 | 640 | 3.6 | 6.9/7.1 |

fURS, flexible ureteroscope; -, no information.

RETROGRADE INTRARENAL SURGERY

1. Past state of retrograde intrarenal surgery

1) History of the flexible ureteroscope

The first fURS, designed by Marshall [4] in 1964, was composed of glass fiber that was used to observe a ureteral stone through a 26-Fr cystoscope. In the early 1970s, Takagi et al. [5] and Takayasu et al. [6] first reported the clinical application of a fiberoptic pyeloureteroscope. A few years later, Bagley et al. [7] published their first clinical outcomes of the use of an fURS for diagnosis and treatment of upper urinary tract disorders. This fURS had a 13-Fr gauge with no working channel or integrated deflecting function. Therefore, the developments of the fURS during that time were mainly related to decreasing the diameter of the device and increasing the deflection angle. In 1991, however, Grasso et al. reported an advanced fURS with a 7.5-Fr tip and an up 120°/down 170° deflection system. In 1998, they published a clinical study of 492 patients using an fURS with a larger 3.6-Fr working channel [8]. Later, in 2001, an fURS with a two-way deflection system (270°/270°) and stronger durability was introduced to the market, improving access to the pelvicalyceal system [9]. With continued progress in technological developments thereafter, the first digital fURS was manufactured in 2006. This digital fURS provided better image quality and was much lighter in weight because of the integrated light cable and camera head within the ureteroscope, which improved the surgeon's ergonomics. In 2010, Yinghao et al. [10] described a newly designed ureteroscope termed "Sun's ureteroscope" that had a rigid shaft with a flexible tip. Advancements in endourological technology

have progressed to realize ureteroscopes of much smaller diameter, stronger durability, and improved image quality. Many fURSs from several companies can now be utilized in clinical practice (Table 1).

2) Past indications for retrograde intrarenal surgery

Several decades ago, fURSs were used only for the observation and diagnosis of diseases in the pelvicalyceal system because of the lack of a useful working channel. Therefore, the indications for use of fURSs were limited. In 1986, Streem et al. [11] first described the use of ureteropyeloscopy for evaluation of upper tract filling defects. In 1990, Bagley and Rivas [12] subsequently reported the diagnosis and management of upper urinary tract filling defects using an fURS. In 1994, Abdel-Razzak et al. [13] first described the performance of biopsy of upper urinary tract tissues through a small working channel in an fURS. Furthermore, Bagley and Erhard [14] reported the first use of a holmium:YAG laser for ureteral stones through the working channel in clinical practice in 1995. Finally in 1998, Bagley [15] published the first ureteroscopic laser treatment of upper urinary tract tumors, which was accomplished using a holmium:YAG laser and neodymium-doped YAG laser.

It has become possible to perform certain procedures through the working channel, such as stone removal, since Grasso and Bagley [8] reported an fURS with a more useful 3.6-Fr working channel. In addition, successful use of the holmium:YAG laser as a flexible lithotripter expedited the treatment of upper urinary tract stones in the late 1990s. In 1998, Grasso et al. [16] reported the clinical outcomes of 51 pa-

tients with medical comorbidities who underwent RIRS for >2-cm upper urinary tract stones. They used small-diameter fiberoptic ureteroscopes and a holmium laser lithotripter with a 200-micron laser fiber. The stone-free rate (SFR) was encouraging at 76% in the first procedure and the postoperative complication rate was 6.2% [16]. Thereafter, many endourologists increasingly utilized the fURS for treatment of upper urinary stones. Sofer et al. [17] reported their experience with 598 patients who underwent ureteroscopy and holmium laser lithotripsy from 1993 to 1999. The average stone size was 11.3 mm, and 56 patients with intrarenal stones were treated using an fURS. The SFR among patients with kidney stones was 84% with a low complication rate of 4% [17].

Until the 1990s, the definite indications for use of an fURS were unclear with the exception of evaluating and diagnosing certain upper urinary tract diseases. The main clinical indications for RIRS seemed to be upper urinary tract stones, especially kidney stones of various sizes. The advancements of fURSSs and the introduction of holmium:YAG lasers to the clinical setting have promoted progression of urolithiasis treatment [18].

2. Present state of retrograde intrarenal surgery

1) Current flexible ureteroscope: single-use flexible ureteroscope

The fURS has become a mainstay of treatment of nephrolithiasis with increasing indications for surgical modalities. Most fURSSs were manufactured as reusable endoscopes. However, reusable fURSSs have high costs associated with production, maintenance, processing, sterilization, repairs, and personnel [19]. Therefore, the cost-effectiveness decreases if an fURS breaks during short procedures. Hennessey et al. [3] conducted an economic analysis of a single-use fURS (LithoVue; Boston Scientific, Marlborough, MA, USA) and a reusable fURS (URF-V; Olympus, Tokyo, Japan). They found that the cumulative cost (costs of purchase, maintenance, and repair) of 28 procedures performed with the

reusable fURS was approximately \$50,000 (average of \$1,786 per case). The cumulative cost was lower with the single-use fURS (approximately \$35,000; average of \$1,200 per case). However, if the price of the single-use fURS were \$2,500, the 28 procedures would cost approximately \$70,000. In such a case, the reusable fURS would be more favorable from a financial standpoint [3,20]. Although the cost-effectiveness of a single-use fURS depends on the price of the instrument, the cost-effectiveness of a reusable fURS is also affected by the number of procedures in which the instrument is used. Martin et al. [21] performed a cost assessment between a single-use fURS (LithoVue) and reusable fURS (Flex-XC; Karl Storz, Tuttlingen, Germany). They found that after 99 ureteroscopic procedures, the cost-benefit analysis favored the reusable fURS over the single-use fURS and concluded that a single-use fURS may be cost-beneficial at centers with a lower annual case volume. However, institutions with a high case volume may find reusable fURSSs to be more cost-beneficial [21].

A single-use fURS can be very beneficial in patients with large stones, complicated lower pole stones, anterior lower pole stones, and an anomalous renal anatomy as well as in training of novices, during which an fURS can be easily damaged [22,23]. Several single-use fURSSs are now available for treatment of upper urinary tract diseases (Table 2). However, although these single-use fURSSs have almost the same specifications, they have a much thicker tip and shaft than reusable fURSSs. Therefore, it is often difficult to access the upper urinary tract in patients with a narrow ureter and when using a ureteral access sheath (UAS) smaller than 10 to 12 Fr. In the current era of endourology, the decision to use a single-use or reusable fURS for treatment of upper urinary tract disease is based on the preoperative evaluation and intraoperative findings in each case.

2) Current indications for retrograde intrarenal surgery

The treatment indications for RIRS have been markedly

Table 2. The specification of single-use fURSSs

| Company | Single-use fURS | Imaging system | Active deflection (up/down; °) | Working channel (Fr) | Length (mm) | Diameter (tip/shaft; Fr) |
|-------------------|--------------------------|----------------|--------------------------------|----------------------|-------------|--------------------------|
| Boston Scientific | LithoVue | CMOS | 270/270 | 3.6 | 680 | 7.7/9.5 |
| PUSEN | Uscope UE3022 | CMOS | 270/270 | 3.6 | 630 | 9.5/9.5 |
| Neoscope Inc | Neo Flex | CMOS | 280/280 | 3.6 | - | -/9.0 |
| YouCare Tech | YC-FR-A | CMOS | 270/unilateral | 4.2 | - | -/8.0 |
| OTU medical | Wiscope | - | 275/275 | 3.6 | 905 | 7.4/8.6 |
| Karl-Storz | Video uretero-renoscopes | CMOS | 270/270 | 3.6 | 700 | -/8.5 |

fURS, flexible ureteroscope; -, no information.

extended with the advancements in endoscopic technology and lithotripters, such as laser systems. The European Association of Urology (EAU) guidelines on urolithiasis state that RIRS can generally be applied in patients without specific contraindications, such as an untreated urinary tract infection (UTI). The guidelines also suggest that the indications for RIRS include renal stones of <20 mm that are unsuitable for shock wave lithotripsy (SWL); an unfavorable anatomy for SWL, such as a steep infundibular-pelvic angle, long lower pole calyx, and narrow infundibulum; lower pole stones of >15 mm not feasible for SWL; the patient's preference for kidney stone treatment; and the patient's social situation (e.g., professions involving travel, such as a pilot) (Fig. 1) [24,25]. The other possible indications for RIRS in patients with kidney stones include radiolucent stones, multiple renal stones unfeasible for SWL, treatment with anticoagulants, coexistence of renal and ureteral stones, and bleeding disorders [25]. In general, the first recommended treatment option for >20-mm kidney stones is percutaneous nephrolithotomy (PCNL). However, the current surgical techniques of RIRS and laser lithotripsy make it possible to perform minimally invasive treatment for >20-mm kidney stones. In a recent systematic review and meta-analysis, the SFR of 20- to 35-mm kidney stones treated by RIRS was 71% to 95% [26,27]. However, although it is possible for highly skilled surgeons to successfully perform single procedures

for larger kidney stones, several staged procedures are usually required to achieve a stone-free status. In addition, multisection RIRS might be needed to avoid severe complication such sepsis, septic shock, and longer operation time in high risk patients with many comorbidity, infected stone as well as larger stone >20-mm. Therefore, decisions regarding RIRS for larger kidney stones should be made with comprehensive consideration of various risk factors including the surgeon's experience, the patient's comorbidities and preferences, and the equipment available at the institution [28,29].

3) Favorable indications for single-use flexible ureteroscope in retrograde intrarenal surgery

A single-use fURS has specific indications in RIRS, including large, hard kidney stones; lower pole stones with an acute infundibular-pelvic angle; anterior lower pole stones; drug-resistant bacteria in urine culture; an anomalous renal anatomy; and use by novice trainees. These situations easily induce damage to the fURS during procedures. Therefore, a single-use fURS would be optimal if the surgical findings during RIRS allow its use [30].

4) Potential indications for retrograde intrarenal surgery

With the continued technological developments in endourology, the indications for RIRS have mainly focused on

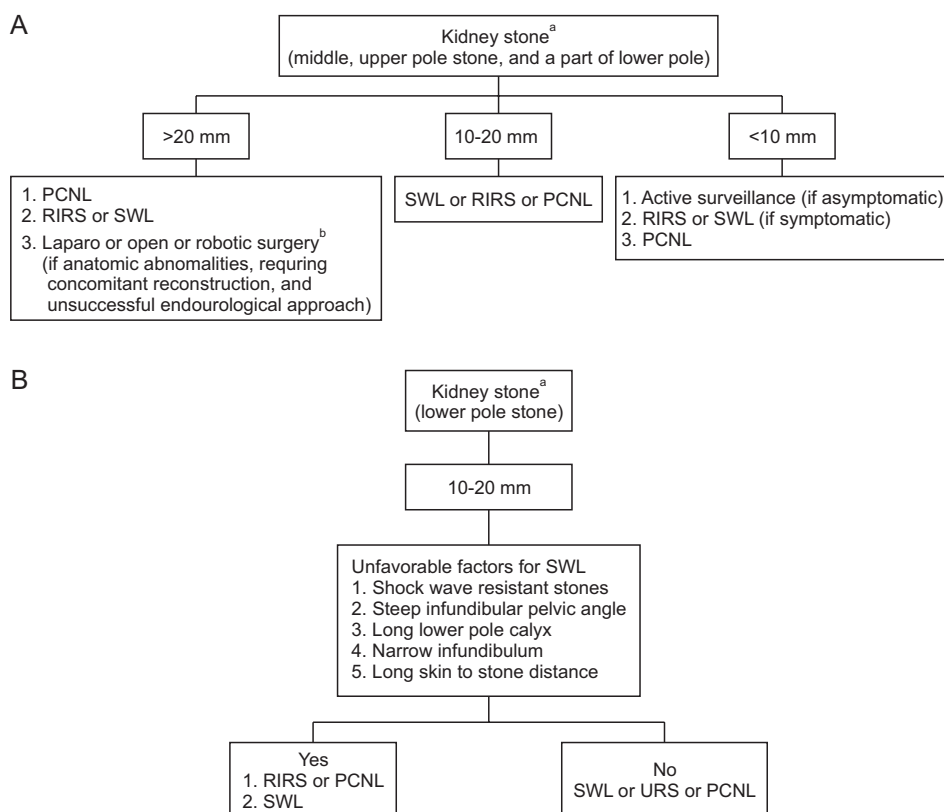


Fig. 1. Flow chart of kidney stone management. (A) Middle, upper pole stone, and part of lower pole. (B) Lower pole stone. PCNL, percutaneous nephrolithotomy; RIRS, retrograde intrarenal surgery; SWL, shock wave lithotripsy; URS, ureteroscopy. ^a:If uncorrected bleeding diatheses or continuous anticoagulation/antiplatelet therapy, URS should be use. ^b:If negligible kidney function, nephrectomy is one of treatment.

diseases such as UTUC, ureteral stricture, and ureteropelvic junction stenosis. One recent topic of interest is ureteroscopic treatment of UTUC by laser ablation using a holmium:YAG laser or thulium:YAG laser. The EAU guidelines suggest nephron-sparing management as the primary treatment option not only in patients with low-risk tumors (unifocal, <2 cm in size, low-grade cytology, low-grade fURS-obtained biopsy, and no invasive aspect on computed tomography urography) but also in patients with kidney deficiency and severe comorbidities [31,32]. The role of RIRS in the management of UTUC will be increasingly extended in the field of endourologic oncology.

5) Surgical steps of retrograde intrarenal surgery

Acquiring the adequate manipulation in RIRS is not easy way. Therefore, flexible ureteroscopic experience during residency is important for the maintenance and development of skills, even though they appear to plateau after 1 year. Botoca et al. [33] evaluated how accumulating experience led to a satisfactory level of skills. The acceptable level of skills was defined as the moment when the rates of success and complications showed a tendency to plateau at a level similar to the results mentioned in the EAU guidelines [33]. The tendency to plateau appeared after approximately 50–60 procedures in the study [34]. The ureteroscopy learning curve is relatively long although we should not forget that individual skills may differ and each urologist may have their own learning curve pattern. Therefore, endourological basic and advanced training such as using bench model or virtual reality simulator is important to promote and keep fURS technical skill [35]. Furthermore, if making a false step of fURS handling, they are easily damaged during RIRS procedure, post-operative sterilization, and processing due to quite fragile characteristics. Therefore, we should figure out the handling methods and accomplish gentle manipulation.

(1) Role of semi-rigid ureteroscope

Semi-rigid ureteroscopes are mainly utilized for the active management of ureteral stones, direct axial dilation of the distal ureter and ureteral strictures, and the diagnosis of ureteral tumors. However, semi-rigid ureteroscopes are also used in RIRS to examine the ureteral stone, check for ureteral relaxation, and assess the extent of the lumen. Selection of an appropriately sized UAS is very important for negotiation of the renal collecting system [36].

Karabulut et al. [37] investigated the efficacy of placing the UAS without the obturator over a semi-rigid ureteroscope under direct vision as the technique of inserting the

UAS into the ureter in RIRS [36]. This method protects the surgeon and patients from radiation exposure by shortening the fluoroscopy and operating times [37].

(2) Safety guide wire

In the first published manual on endourology in 1983, Clayman et al. [38] described the proper retrograde use of a 0.035- to 0.038-inch wire as a safety guide wire (GW). In 1987, Ekman et al. [39] reported the first use of a safety GW in a patient undergoing ureteroscopic stone removal. During the past three decades, the safety GW has become an indispensable device in ureteroscopic surgery for ensuring direct access to the collecting system or ureter, decreasing loss of disorientation in the ureter, avoiding intraoperative complications such as ureteral injury and perforation, and facilitating insertion of a ureteral stent in cases of failed retrograde ureteroscopic procedures. However, the use of a safety GW increases the resistance to passage of the ureteroscope. In particular, the presence of a safety GW interferes with manipulation of the fURS. Because of current advancements in miniaturized instruments (e.g., ureteroscope and UAS) and the development of endourological techniques, routine intraoperative placement of a safety GW might not be needed. Patel et al. [40] reported a 26% complication rate in a series of 268 ureteroscopic procedures without a safety GW, with no perforations or avulsions. Dickstein et al. [41] published a series of 305 ureteroscopic procedures, 270 (89%) of which were uncomplicated even without placement of a safety GW. However, the remaining 11% of cases required a safety GW because of obstructing ureteral stones, crushed ureteral stones, and difficult access due to an abnormal anatomy [41]. Similarly, a safety GW is not required in our institution when performing RIRS with a UAS because the placement of a UAS in the upper ureteral portion to access the renal pelvis substitutes for a safety GW. Therefore, insertion of a UAS in RIRS increases ureter safety intraoperatively. However, the EAU guideline generally recommends placement of a safety GW in accordance with best clinical practice in ureteroscopy [42]. In particular, a safety GW should be placed for increased ureteral safety in difficult cases, such as an impacted ureteral stone, stricture, aberrant anatomy, or tortuous ureter, as well as during training of novices.

(3) Ureteral access sheath

The first UAS was described as a “guide tube” by Takayasu and Aso [43] in 1974. They utilized a UAS to access the proximal ureter with a rigid ureteroscope. The UAS has become an increasingly popular instrument for treatment of kidney stones and other diseases in the collecting system

Table 3. Available UAS

| Company | UAS | Length (cm) | Diameter (inner/outer; Fr) | Lumen |
|-------------------|-----------------|--------------------|-----------------------------------|-------|
| COOK Medical | Flexor | 20, 28, 35, 45, 55 | 9.5/11.5, 10.7/12.7, 12/14, 14/16 | 1 |
| COOK Medical | Flexor parallel | 20, 28, 35, 45, 55 | 9.5/11.5, 10.7/12.7, 12/14, 14/16 | 1 |
| Coloplast | Retrace | 35, 45 | 10/12, 12/14 | 1 |
| Boston Scientific | Navigator HD | 28, 36, 46 | 11/13, 12/14, 13/15 | 1 |
| Boston Scientific | Navigator NEO | 28, 36, 46 | 11/13, 12/14, 13/15 | 1 |
| Olympus | UroPass | 24, 38, 54 | 10/12, 12/14 | 1 |
| BARD | Proxis | 25, 35, 45 | 10/12, 12/14 | 1 |
| BARD | AQUAGUIDE | 35, 45 | 10 (12)/14, 11 (13)/15 | 2 |
| Rocamed | Bi-Flex | 35, 45 | 10/12, 12/14 | 1 |
| Takai | J Flexisheath | 28, 35, 45, 55 | 11/13, 12/14 | 1 |

UAS, ureteral access sheath.

during RIRS. A UAS has many advantages, including easy reentry of the fURS into the collecting system, prevention of increased intrarenal pressure, maintenance of visualization in the surgical field to facilitate saline irrigation, and use as a possible substitute for a safety GW [25,44]. Various UAS sizes ranging from 9.5/11.5 to 14/16 Fr in diameter and from 20 to 55 cm in length are now available for clinical use (Table 3). However, selection of the UAS size mostly depends on the surgeons performing the procedure. Ureteral injury may easily occur if using a UAS larger than the actual ureteral lumen diameter. Traxer and Thomas [45] reported that UAS-related ureteral wall injuries occurred in 46.5% of RIRS procedures when using a 12- to 14-Fr UAS. They suggested that the ureteral injury severity determines the grade of injury in terms of the depth of ureteral damage, with a low-grade injury classified as grade 0 or 1 and a high-grade as grade 2, 3, or 4/5. Grade 2 injuries involve the ureteral smooth muscle layer (10.1%) and grade 3 injuries involve full-thickness ureteral perforation (33%) [45]. Generally, the incidence of ureteral injury using a UAS depends on the relationship between the ureteral diameter and UAS size. Although the standard UAS size in the United States and Europe seems to be 12 to 14 Fr, the Asian standard might be 11 to 13 Fr or even smaller because of differences in body size.

Interestingly, one of the current topics in use of a UAS is intrarenal pressure. As mentioned above, the UAS facilitates the irrigation inflow and outflow of saline. High intrarenal pressure during procedures may cause urosepsis or a subcapsular renal hematoma. According to some research, pyelosis, pyelovenous, and pyelolymphatic backflow of irrigating solution might occur at intrarenal pressures above 40 cmH₂O [46]. Therefore, keeping the intrarenal pressure below the limit for intrarenal and pyelosis backflow might prevent complications during RIRS. Auge et al. [47] reported that a UAS can protect the kidney by reducing the

intrarenal pressure by 57% to 75% during RIRS. Additionally, using a thicker UAS intraoperatively can decrease the intrarenal pressure [48]. However, the irrigation inflow and outflow of saline through a 9.5- to 11.5-Fr UAS is poor. A UAS of this size may result in excessive intrarenal pressure during RIRS. Therefore, the minimum standard UAS size of 10 to 12 Fr is needed to acquire acceptable irrigation inflow and outflow of saline and thus maintain good surgical visualization. In addition, different intrarenal pressures and saline outflow are produced among the various kinds of available 10- to 12-Fr UASs. Among UASs of this size, the Bi-Flex (Rocamed, Monaco) and UroPass (Olympus) induce lower intrarenal pressure than the ReTrace (Coloplast, Humlebæk, Denmark) and Proxis (C.R. Bard, Murray Hill, NJ, USA) because of their different inner diameters [49].

(4) Irrigation methods: maintenance of surgical field

In endourological surgery, saline irrigation is mandatory to open and maintain the surgical field. Visualization of the surgical field is maintained through optimal irrigation of saline. The irrigation methods used during RIRS have evolved during the past few decades. Lyon et al. [50] first reported the use of an fURS with irrigation connected to the ureteroscopic working channel and used gravity to maintain the irrigation flow by placing a saline bag 30 cm above the level of the kidney. A handheld activated syringe-based system was historically used as the standard method of gravity-induced saline irrigation during RIRS. A foot-activated syringe-based system is currently available (Peditrol; Wismed, Durban, South Africa) [51]. In addition, pressurized irrigant bags and an automatic irrigation pump (AIP) have been introduced for irrigation during endourological procedures. The view of the surgical field during RIRS has changed because of increased efficiency of the irrigation flow, which

is influenced by the location and size of the UAS, size of the fURS, and irrigation method. Irrigation inflow and outflow through the UAS during RIRS is required to open and maintain optimal renal pelvic distention, good visualization, and low intrarenal pressure. A handheld activated syringe-based system is commonly used to achieve adequate renal pelvic distention and a good surgical view. However, a handheld activated syringe-based pump and a foot-activated syringe-based system may increase the risk of perioperative pyelonephritis and sepsis secondary to high intrarenal pressure. Therefore, it is crucial to maintain a constant irrigation flow regardless of the type of instruments in the working channel and ensure an adequate surgical field to prevent the drastic increases in the intrarenal pressure that might occur with a handheld activated syringe-based system [52]. An AIP may help to maintain an optimal surgical field for easy manipulation of the fURS during RIRS. Lama et al. [53] reported the use of an AIP for irrigation that maintains the same irrigation flow over time in contrast to gravity irrigation. In addition, Inoue et al. [52] recently reported that the irrigation flow from the tip of the fURS remains almost unchanged by adjusting the pressure control in the AIP system even when instruments are placed through the working channel of the fURS. Therefore, the use of an AIP system during RIRS might help to maintain the surgical field and thus manipulate the fURS with comfort.

(5) Laser instruments and various settings

In RIRS, the holmium:YAG laser system has been the gold standard lithotripsy instrument for stone management since Denstedt et al. [54] first described its use in endourology in their preliminary report in 1995. Various laser systems with high efficacy and excellent safety profiles are currently available for stone lithotripsy (Table 4). Traditionally, laser lithotripsy only allowed for adjustment of the pulse energy and frequency. However, the pulse duration (width) can now be utilized for stone disintegration. Therefore, stone endourologists can manipulate these three parameters to perform fragmentation using a lower frequency (5–15 Hz) and higher energy setting (0.6–1.2 J) with a short or long pulse duration or perform dusting using a high frequency (50–80 Hz) and low energy setting (0.2–0.5 J) with a short or long pulse duration depending on the particular clinical situation and stone hardness [55]. The clinical advantages of a long pulse mode over a short pulse mode are less stone re-ropulsion, less fiber degradation, and greater stone dust [56]. Stone fragmentation involves the creation of fragments that can be extracted through the UAS with a basket, whereas stone dusting involves the creation of tiny stone particles of

Table 4. Recent available various Holmium:YAG laser system

| Characteristic | Lumenis | | Quanta | | Richard Wolf | | EMS | | LISA | | DiREX | | Trimedynne | | Star medtec | | Convergent | | Olympus | |
|----------------------|---------------|------------|------------------|-------------------|-------------------|-------------|-----------------------------|------------|-------------------|--------------|--------|----------------|------------|------------|-------------|-----------|------------|-----|---------|-----|
| | Pulse 30H/50H | Pulse 100H | Pulse 120H | Versa Pulse Suite | Versa Pulse Suite | Laser litho | Cyber Ho | Mega pulse | Swiss Laser clast | SPHINX | Themis | Omni Pulse MAX | 30W Auriga | Odyssey 30 | HLS 30W | | | | | |
| Laser specifications | Ho | Ho | Ho | Ho | Ho | Ho | Ho | Ho | Ho | Ho | Ho | Ho | Ho | Ho | Ho | Ho | Ho | Ho | Ho | Ho |
| Max power output (W) | 30/50 | 100 | 120 | Ho/Nd | 80/100 | 30 | 60/100 | 30/70 | 20 | 45/60/80/100 | 30 | 30 | 30/50 | 30 | 30 | 30/50 | 30 | 30 | 30 | 30 |
| Laser energy (J) | 5.0/3.5 | - | ≥0.2 | 0.2–3.5 | 0.2–2.8 | ≤4.0 | ≤5.0 | ≤4.0/≤5.0 | ≤3.5 | 0.5–4.5 | ≤3.0 | ≤7.0 | ≤4.0/≤4.2 | - | - | ≤4.0/≤4.2 | - | - | - | - |
| Max pulse rate (Hz) | 25 | - | 80 | 50 | 50 | 25 | 100 | 25/60 | 20 | 30 | - | 60 | 20/25 | - | - | 20/25 | - | - | - | - |
| Stone dusting effect | (+) | (+) | (+) | (+) | - | (+) | (+) | (+) | (+) | (+) | (+) | - | - | (+) | (+) | -(+) | (+) | (+) | (+) | (+) |
| Special mode | (-) | (-) | Moses technology | (-) | (-) | (-) | Virtual Basket Vapor tunnel | (-) | (-) | (-) | (-) | (-) | (-) | (-) | (-) | (-) | (-) | (-) | (-) | (-) |

YAG, yttrium aluminium garnet; Ho, holmium-YAG laser; Ho/Nd, holmium-YAG/Neodymium; -, no information.

<2 mm that can be spontaneously passed with no basketing [57]. However, one currently advocated definition of stone dust (particles of <250 μm) defines dust as particles small enough to meet the following criteria: spontaneous floating under 40 cmH_2O irrigation pressure, mean sedimentation time of <2 seconds through 10 cm of saline solution, and full suitability for aspiration through a 3.6-Fr working channel [58]. According to data from the Endourological Society worldwide survey in 2014, 26.7% of 414 endourologists from 44 countries actively removed all stone fragments with a basket, whereas 37.4% retrieved only larger fragments but not small fragments. The stone dusting technique has been increasingly applied in Western countries because of the difficulty of stone basketing for fragments [59]. However, Humphreys et al. [60] examined whether the SFR is better with dusting or basketing during RIRS. They concluded that the short-term SFR was higher with active basket retrieval of fragments (74.3% vs. 58.2%). El-Nahas et al. [61] also reported that the dusting technique had a shorter operation time, whereas the fragmenting technique led to a significantly higher SFR (78.6% vs. 58.6%). The combination of fragmenting and dusting may be a more feasible method to break stones. Endourologists choose one of these methods depending on the situation encountered during surgery (including the stone size, stone composition, stone location, impaction of stone, stone retropulsion, and surgeon preference) to improve the effectiveness and outcome of surgery.

High-power holmium:YAG laser therapy with Moses Technology by Lumenis (Clarion Medical Technologies, Cambridge, ON, Canada) has recently become available in clinical practice. Furthermore, Virtual Basket mode in Cyber-Ho (Quanta System SpA, Samarate, Italy), which is similar to Moses Technology, has also been introduced. Moses Technology has improved the stone fragmentation capacity by increasing the energy transmission in water and reducing stone retropulsion compared with the long pulse mode [62]. Therefore, Moses Technology is capable of much less stone retropulsion. In addition, Moses Technology produces more pronounced disruption of morphological characteristics because it may deliver a superior laser beam through a vapor channel compared with the conventional holmium:YAG laser. Higher local temperatures occur during the use of Moses Technology (direct photothermal effect) [63]. Therefore, Moses Technology can create a large amount of tiny stone dust fragments; this is termed the “snow globe effect.” In their *in vitro* study, Elhilali et al. [62] reported that the Moses mode resulted in a significantly higher stone ablation volume (160% higher) and less stone movement (50 times less retropulsion) than the regular mode. Ibrahim et al. [64]

recently published a randomized clinical trial showing that the Moses mode was associated with a significantly shorter pulverization time and procedural time than the regular mode. In addition, there were no significant differences in the success rate at the end of 3 months (83.3% vs. 88.4%) or intraoperative complications between the Moses mode group and regular mode group. However, one patient required endoureterotomy for ureteral stricture in the Moses group [64]. Thus, close attention should be paid to the risk of thermal injury and resultant ureteral stricture when using high-power holmium:YAG laser therapy [65].

As a cutting-edge instrument in the field of stone lithotripsy, the thulium fiber laser was launched to disintegrate urinary tract stones. Comparison of the differences between a holmium laser and thulium fiber laser translate into multiple potential advantages in favor of the thulium fiber laser, such as a four-fold higher absorption coefficient in water, smaller operating laser fibers (50- to 150- μm core diameter), lower energy per pulse (as low as 0.025 J), and higher maximal pulse repetition rate (up to 2,000 Hz). Comparative *in vitro* studies have shown a 1.5- to 4.0-times faster stone ablation rate and much lower stone retropulsion with the thulium fiber laser than holmium laser [66,67]. This innovative laser technology is particularly advantageous for RIRS and may become the next important therapeutic milestone.

(6) Role of preoperative and postoperative ureteral stenting

Preoperative stenting for kidney stone treatment has advantages including a higher SFR, lower incidence of intraoperative complications (especially ureteral injuries), and greater facilitation of UAS placement. Preoperative stenting for patients without perioperative infection, severe self-symptom, anatomical abnormalities, and/or tortuous ureters is not mandatory in most clinical settings for access to the upper urinary tract because it induces hematuria, pain, urgency, and a risk of febrile UTI. However, most endourologists have experienced failed access to the upper urinary tract because of a tight or difficult ureter (8.4%–16.0%) [68,69]. Once failed access has occurred, staged procedures are required to achieve passive ureteral dilation 1 to 2 weeks after placing the ureteral stent in the first ureteroscope.

Postoperative stenting is a quite standard procedure after ureteroscopic surgery not only to prevent ureteral obstruction due to mucosa edema and ureteral healing but also to avoid ureteral injury, perforation, residual fragments, bleeding, and UTI. However, the optimal duration of postoperative ureteral stenting is unknown. The indwelling time preferred by most urologists appears to be 1 to 2 weeks

after ureteroscopy. However, routine postoperative stenting is not required if no ureteral injury is observed under direct ureteroscopic vision at the end of the ureteroscopic surgery, even in patients who undergo uncomplicated ureteroscopy for impacted ureteral stones [70,71]. Postoperative stenting might be associated with higher postoperative morbidity and costs [31]. Byrne et al. [72] reported that flank discomfort on postoperative day 1 was significantly less common in patients who did not undergo stenting; however, there was no significant difference in patient-reported postoperative hematuria between those who did and did not undergo stenting. With the recent advancements of smaller instruments for ureteroscopic treatment, the number of patients who do not need postoperative stenting has increased. However, how to determine which patients do not require postoperative stenting after ureteroscopic surgery remains unclear.

6) Surgeon's safety from radiation exposure

Extended low-dose radiation exposure can greatly affect human health in the long term, resulting in an increased incidence of malignancies including thyroid cancer, breast cancer, and leukemia [73]. In the current urological field, radiation exposure among medical personnel and patients has increased. Therefore, urologists must be aware of the risk of harmful effects caused by radiation exposure. A major source of radiation exposure for surgeons and medical staff members is scattered radiation produced by interaction of the primary radiation beam with the patient's body and the operating table. Although the dose limit of medical exposure for patients has not been established, the occupational radiation exposure dose limit has been defined as 50 mSV per year by the National Council on Radiation Protection and Measurements [74]. The International Commission on Radiological Protection has recommended limiting radiation exposure to levels "as low as reasonably achievable (ALARA)" [75].

Medical radiation protection principles should be applied for both the patients and medical staff members involved in imaging, the latter of which include surgeons, nurses, and medical engineers. The following are general methods to optimize radiation protection.

- ① Time: the radiation exposure time should be minimized in terms of both the fluoroscopy time and the quantity of X-ray photographs acquired.
- ② Distance: medical staff members should position themselves as far as possible from the X-ray source.
- ③ Shielding: medical staff members should use adequate shielding materials, such as lead aprons, lead glasses, and lead radiation-shielding glass.

Shielding for such personnel is usually performed by

wearing personal protective clothing. The standard lead protection protocol requires the use of a 0.35-mm lead apron and thyroid shield by the operating surgeon and 0.25-mm lead aprons for other personnel [76]. However, protection from scattered radiation by protective clothing is incomplete, especially that to the arms, eyes, and brain.

In the endourological field, PCNL using radiologic guidance was initially described by Fernström and Johansson [77], who performed this procedure in three patients in 1976. In PCNL, the mean radiation exposure dose for the surgeon is 12.7 mSV per procedure. This value is higher than the dose of 11.6 mSV per exposure in flexible ureteroscopy because of the longer fluoroscopic time and close distance between the radiation source and the surgeon [78]. The mean fluoroscopy screening time during PCNL reportedly ranges from 4.5 to 6.04 minutes (range, 1–12.16 min) [79]. Furthermore, one study showed that the mean radiation exposure to the surgeon's finger and ocular region was 0.28 and 0.125 mSV, respectively, because of the non-uniform radiation exposure caused by scattered radiation [80]. Therefore, the operator's hands and eyes should also be protected from scattered radiation exposure using gloves and glasses with lead-threading. Most endourologists generally perform needle puncture for renal access under fluoroscopy. Therefore, an ultrasound-guided approach is beneficial because it offers better protection to surgeons from radiation exposure during PCNL than does the fluoroscopic approach. The surgeon's radiation dose is lower in ureteroscopy than in PCNL in almost all cases because ureteroscopy is characterized by a shorter fluoroscopic time and longer distance between the radiation source and surgeon. Pulsed fluoroscopy was introduced to reduce the radiation dose by limiting the X-ray exposure time and number of exposures per second. The duration of exposure during ureteroscopy has been decreased from the original 47 minutes to 0.62 minutes, and the mean fluoroscopy screening time during ureteroscopy is reportedly 44.1 seconds (range, 36.5–51.6 s) [81]. Kokorowski et al. [82] described the efficacy of a preoperative checklist related to radiation protection. The checklist was useful for decreasing radiation exposure during procedures. Furthermore, Inoue et al. [83] reported that using protective lead curtains on both sides of the patient table, the operating table end, and the image intensifier was useful for reducing the surgeon's radiation exposure during ureteroscopy. The presence of protective lead curtains caused a 75% to 80% reduction of the scattered radiation dose compared with the absence of lead curtains. Novel shielding curtains containing bismuth and antimony, which are also suitable for radiation protection because of their high density and potential weight savings compared

with lead, have also been designed. In modern radiation protection practice, active personal dosimeters are essential to satisfy the ALARA principle. Most urologists have an insufficient perception of their own personal radiation protection. A previous study showed that although 84.4% of urologists who were chronically exposed to ionizing radiation wore lead aprons, only 53.9% wore a thyroid shield and only 27.9% wore eyeglasses with lead linings. Moreover, only 23.6% of urologists wore a personal dosimeter [84]. Awareness of occupational radiation exposure among physicians in the urological field remains low. Although the risks of harmful effects of occupational radiation exposure may be relatively low, they should not be ignored. On our best knowledge, they describe the various preventive methods from radiation exposure during operation (Table 5).

3. Future state of retrograde intrarenal surgery

1) Possible indications for retrograde intrarenal surgery

Various laser systems can be used in RIRS, including a high-power holmium:YAG laser (120 W) with Moses Technology, thulium fiber laser, thulium:YAG laser, and neodymium-doped YAG laser. All of these are promising treatment options for several diseases in patients undergoing RIRS. In addition, a single-use fURS can provide safe and easy access to the kidney anatomy.

The indications for treatment of kidney stones are expected to expand to include larger stones of >2 cm in future guidelines; less basketing is being performed because of the ability to create large amounts of stone dust (snow globe

effect), and surgical access has improved in patients with a difficult renal pelvic anatomy, even when the lower pole has an anatomically acute angle. In addition, for patients with multifocal <3-cm UTUC with low-grade pathological findings and no invasive aspect on computed tomography urography, retrograde endourological procedures might become a more common treatment. Furthermore, novel laser systems might help to manage postoperative ureteral stricture, symptomatic renal cysts, and recurrent ureteropelvic junction stenosis [85,86].

2) New trends in retrograde intrarenal surgery

(1) New flexible ureteroscope with joystick

Usually, fURS manipulation involves torque movement of the hand, back-and-forth movement of the fURS shaft, and up-and-down movement of the fURS lever. Surgeons must perform optimal manipulation in a coordinated manner by combinations of these complicated maneuvers, which may be difficult in some cases. A new fURS with an omnidirectional bending tip using a joystick unit integrated into a handgun-type control unit was recently introduced. Inoue et al. [87] first reported that this novel fURS provided a greater range of reach along all directions in the lower-pole calyx compared with some usual fURSs in their *ex vivo* study. Tambo et al. [88] subsequently investigated whether a conventional fURS or novel joystick fURS is easier to manipulate in their initial constructive validation study. They found that the novel joystick fURS allowed for much better manipulation by novice trainees and provided better ergonomics for surgeons. This joystick fURS might have benefits in terms of ureteroscopic performance [88].

(2) Thulium versus high-power holmium laser therapy

High-power holmium:YAG lasers have long been available for management of upper urinary tract stones. Like Moses Technology, the Virtual Basket mode is a special technology that is quite beneficial in terms of producing tiny particles of stone dust by two forms of ablation: the photothermal effect and photomechanical effect. In addition, the novel thulium fiber, which is capable of more quickly producing large amounts of tiny stone dust than the holmium:YAG laser *in vivo*, has been introduced to clinical use. Therefore, the stone management strategy during RIRS has changed from more stone basketing to less stone basketing or no stone basketing. The differences in the clinical outcomes between the two laser systems are unclear. However, further refinement of how to use these laser systems will be a key point in the management of stones, UTUC, and other

Table 5. Reduction technique from radiation exposure for patients and operators during surgery

| Instrument/operator | Preventive technique |
|---------------------|--------------------------------------------------------------------------------------------------------------------------------------------------------------------------------------------------------------------------------------------------------------------------------------------------------------------|
| Image intensifier | <ol style="list-style-type: none"> ① Maximizing the distance between the X-ray tube and the patient ② Minimizing the distance between patients and the image Intensifier |
| C-arm | <ol style="list-style-type: none"> ① Collimating of image monitor ② Using pulsed fluoroscopic mode |
| Operator | <ol style="list-style-type: none"> ① Minimizing fluoroscopy time ② Protective shielding for operator; wearing eyeglass, lead apron, thyroid shield ③ Protective shielding of patient table |
| Others | <ol style="list-style-type: none"> ① Using ultrasound instead of fluoroscopy ② Direct retrograde endoscopic vision combined with ultrasound in PCNL ③ Last image hold ④ Laser guided C-arm ⑤ Dedicated educational training (including pre-operative checklist) |

disorders during RIRS in the coming years.

(3) New stone removal devices

Although stone dusting is beneficial, its SFR is still lower than that produced by stone basketing after RIRS. Therefore, new instruments might be needed to remove the tiny stone dust particles, such as stone vacuum devices or a novel type of basket. One stone vacuum device is currently available in clinical practice. Zhu et al. [89] compared the efficacy between a suctioning UAS and traditional UAS. The suctioning UAS had a significantly higher SFR on postoperative day 1 (82.4% vs. 71.5%), lower incidence of infectious complications (5.5% vs. 13.9%), and shorter operation time (49.7±16.3 min vs. 57.0±14.0 min) [89]. In addition, a new steerable multi-lumen irrigation/aspiration device (K-VAC; Kalera Medical, San Diego, CA, USA) was introduced in 2019. This device can be used to access all calyces and navigate under fluoroscopy to each calyx. The preliminary report showed that it was quite efficient to remove tiny stone dust fragments and achieve a stone-free status [90].

3) Expected trend in retrograde intrarenal surgery: robotic flexible ureteroscopy

In RIRS, scope manipulation can be technically challenging with a conventional hand-operated fURS. Therefore, the education to acquire the technical skills of fURS manipulation, such as hands-on training using a bench model simulator or virtual reality simulator, has recently been expanded [91]. However, such education is provided in limited regions and countries. In addition, there are some other concerns regarding the surgeon's ergonomics, including radiation exposure, the wearing of a heavy lead-protector, and the surgeon's position when operating the fURS. Robotic-assisted fURS technologies have recently been developed to overcome some of these disadvantages [92]. The first robotic fURS (Sensei-Magellan system; Hansen Medical, Mountain View, CA, USA) was reported in 2011. Desai et al. [93] initially attained a 94% technical success rate for stone disintegration and a complete stone clearance rate of 89% among 18 patients with 5- to 15-mm renal calculi using the Sensei-Magellan system. However, this robotic fURS was abandoned because difficulties were encountered in development of the scope design. A few years later, in 2014, Saglam et al. [92] introduced a new robotic fURS system (Roboflex Avicenna; ELMED, Ankara, Turkey). The Roboflex consisted of a console for operation by the surgeon and a robotic arm for the fURS. The authors preliminarily reported the clinical efficiency and safety of the Roboflex in 81 consecutive patients; the clinical outcomes included a short robot docking time

of 59.6 s, feasible operation time of 74 min, and comparable SFR of 96%, all of which were quite acceptable compared with the conventional hand-operated fURS [92]. In addition, the Roboflex provided significant advantages in terms of the surgeon's ergonomics [93,94]. Therefore, the system gained CE (Communauté Européenne) approval for use in Europe in 2013, but Food and Drug Administration approval is still pending. Although the Roboflex might be optimal in terms of clinical use, it has some limitations included difficulty of stone removal, hand-operated insertion of the UAS, and difficult adjustment of kidney movement. However, the newly available high-power holmium:YAG laser and thulium fiber laser are able to produce large amounts of tiny stone dust particles and may become the next revolutionary technology in robotic-assisted RIRS [26,95].

CONCLUSIONS

The endourological technology in RIRS has continued to advance. The single-use fURS, high-power holmium:YAG laser, and thulium fiber laser may be the next key players in RIRS. Furthermore, robotic-assisted fURS systems have helped to standardize surgical technical skills and produce more sustainable surgical outcomes, more comfortable surgeon ergonomics, much less radiation exposure, and much less surgeon fatigue. Although there are still issues to resolve in RIRS, endourological procedures are expected to expand the range of treatment indications and become much less invasive surgical treatment options for patients and surgeons.

CONFLICTS OF INTEREST

The authors have nothing to disclose.

ACKNOWLEDGMENTS

We thank Angela Morben, DVM, ELS, from Edanz Group (<https://en-author-services.edanzgroup.com/ac>), for editing a draft of this manuscript.

AUTHORS' CONTRIBUTIONS

Research conception and design: Takaaki Inoue. Drafting of manuscript: Takaaki Inoue. Revision of manuscript: Shinsuke Okada, Shuzo Hamamoto, and Masato Fujisawa.

REFERENCES

1. Assimos D, Krambeck A, Miller NL, Monga M, Murad MH, Nelson CP, et al. Surgical management of stones: American Urological Association/Endourological Society Guideline, part I. *J Urol* 2016;196:1153-60.
2. Türk C, Knoll T, Petrik A, Sarica K, Skolarikos A, Straub M, et al. EAU guidelines on urolithiasis: specific stone management of ureteral stones [Internet]. Arnhem: European Association of Urology; 2016 Mar [cited 2017 Nov 8]. Available from: <https://uroweb.org/wp-content/uploads/EAU-Guidelines-Urolithiasis-2016-1.pdf>.
3. Hennessey DB, Fojecki GL, Papa NP, Lawrentschuk N, Bolton D. Single-use disposable digital flexible ureteroscopes: an ex vivo assessment and cost analysis. *BJU Int* 2018;121 Suppl 3:55-61.
4. Marshall VF. Fiber optics in urology. *J Urol* 1964;91:110-4.
5. Takagi T, Go T, Takayasu H, Aso Y. Fiberoptic pyeloureteroscopy. *Surgery* 1971;70:661-3 passim.
6. Takayasu H, Aso Y, Takagi T, Go T. Clinical application of fiber-optic pyeloureteroscopy. *Urol Int* 1971;26:97-104.
7. Bagley DH, Huffman JL, Lyon ES. Flexible ureteropyeloscopy: diagnosis and treatment in the upper urinary tract. *J Urol* 1987;138:280-5.
8. Grasso M, Bagley D. Small diameter, actively deflectable, flexible ureteropyeloscopy. *J Urol* 1998;160:1648-53; discussion 1653-4.
9. Ankem MK, Lowry PS, Slovick RW, Munoz del Rio A, Nakada SY. Clinical utility of dual active deflection flexible ureteroscope during upper tract ureteropyeloscopy. *Urology* 2004;64:430-4.
10. Yinghao S, Yang B, Gao X. The management of renal caliceal calculi with a newly designed ureteroscope: a rigid ureteroscope with a deflectable tip. *J Endourol* 2010;24:23-6.
11. Strem SB, Pontes JE, Novick AC, Montie JE. Ureteropyeloscopy in the evaluation of upper tract filling defects. *J Urol* 1986;136:383-5.
12. Bagley DH, Rivas D. Upper urinary tract filling defects: flexible ureteroscopic diagnosis. *J Urol* 1990;143:1196-200.
13. Abdel-Razzak OM, Ehya H, Cubler-Goodman A, Bagley DH. Ureteroscopic biopsy in the upper urinary tract. *Urology* 1994;44:451-7.
14. Bagley D, Erhard M. Use of the holmium laser in the upper urinary tract. *Tech Urol* 1995;1:25-30.
15. Bagley DH. Ureteroscopic laser treatment of upper urinary tract tumors. *J Clin Laser Med Surg* 1998;16:55-9.
16. Grasso M, Conlin M, Bagley D. Retrograde ureteropyeloscopic treatment of 2 cm. or greater upper urinary tract and minor Staghorn calculi. *J Urol* 1998;160:346-51.
17. Sofer M, Watterson JD, Wollin TA, Nott L, Razvi H, Denstedt JD. Holmium:YAG laser lithotripsy for upper urinary tract calculi in 598 patients. *J Urol* 2002;167:31-4.
18. Van Cleynenbreugel B, Kılıç Ö, Akand M. Retrograde intrarenal surgery for renal stones - part 1. *Turk J Urol* 2017;43:112-21.
19. Tom WR, Wollin DA, Jiang R, Radvak D, Simmons WN, Preminger GM, et al. Next-generation single-use ureteroscopes: an in vitro comparison. *J Endourol* 2017;31:1301-6.
20. Scotland KB, Chan JYH, Chew BH. Single-use flexible ureteroscopes: how do they compare with reusable ureteroscopes? *J Endourol* 2019;33:71-8.
21. Martin CJ, McAdams SB, Abdul-Muhsin H, Lim VM, Nunez-Nateras R, Tyson MD, et al. The economic implications of a reusable flexible digital ureteroscope: a cost-benefit analysis. *J Urol* 2017;197(3 Pt 1):730-5.
22. Leveillee RJ, Kelly EF. Impressive performance: new disposable digital ureteroscope allows for extreme lower pole access and use of 365 µm holmium laser fiber. *J Endourol Case Rep* 2016;2:114-6.
23. Salvadó JA, Cabello JM, Moreno S, Cabello R, Olivares R, Velasco A. Endoscopic treatment of lower pole stones: is a disposable ureteroscope preferable? Results of a prospective case-control study. *Cent European J Urol* 2019;72:280-4.
24. Türk C, Petřík A, Sarica K, Seitz C, Skolarikos A, Straub M, et al. EAU guidelines on interventional treatment for urolithiasis. *Eur Urol* 2016;69:475-82.
25. Inoue T, Okada S, Hamamoto S, Yoshida T, Matsuda T. Current trends and pitfalls in endoscopic treatment of urolithiasis. *Int J Urol* 2018;25:121-33.
26. Kang SK, Cho KS, Kang DH, Jung HD, Kwon JK, Lee JY. Systematic review and meta-analysis to compare success rates of retrograde intrarenal surgery versus percutaneous nephrolithotomy for renal stones >2cm: an update. *Medicine (Baltimore)* 2017;96:e9119.
27. Wilhelm K, Hein S, Adams F, Schlager D, Miernik A, Schoenthaler M. Ultra-mini PCNL versus flexible ureteroscopy: a matched analysis of analgesic consumption and treatment-related patient satisfaction in patients with renal stones 10-35 mm. *World J Urol* 2015;33:2131-6.
28. Ricchiuti DJ, Smaldone MC, Jacobs BL, Smaldone AM, Jackman SV, Averch TD. Staged retrograde endoscopic lithotripsy as alternative to PCNL in select patients with large renal calculi. *J Endourol* 2007;21:1421-4.
29. Inoue T, Murota T, Okada S, Hamamoto S, Muguruma K, Kinoshita H, et al.; SMART Study Group. Influence of pelvic caliceal anatomy on stone clearance after flexible ureteroscopy and holmium laser lithotripsy for large renal stones. *J Endourol* 2015;29:998-1005.

30. Ozimek T, Cordes J, Wiessmeyer JR, Schneider MH, Hupe MC, Gilbert N, et al. Steep infundibulopelvic angle as a new risk factor for flexible ureteroscope damage and complicated postoperative course. *J Endourol* 2018;32:597-602.
31. Rouprêt M, Babjuk M, Burger M, Compérat E, Cowan NC, Gontero P, et al. EAU guidelines on upper urinary tract urothelial carcinoma. Disease management [Internet]. Arnheim: European Association of Urology; 2019 Mar [cited 2020 Nov 1]. Available from: <https://uroweb.org/wp-content/uploads/EAU-Guidelines-on-Upper-urinary-Tract-Tumours-2019.pdf>.
32. Kalaitzis C, Zisimopoulos A, Giannakopoulos S, Touloupidis S. Ureteroscopic laser treatment of upper urinary tract urothelial cell carcinomas: can a tumour free status be achieved? *Adv Urol* 2013;2013:429585.
33. Botoca M, Bucuras V, Boiborean P, Herman I, Cumpănas A, Miclea F. The learning curve in ureteroscopy for the treatment of ureteric stones. How many procedures are needed to achieve satisfactory skills? *Eur Urol Suppl* 2004;3:138.
34. Skolarikos A, Gravas S, Laguna MP, Traxer O, Preminger GM, de la Rosette J. Training in ureteroscopy: a critical appraisal of the literature. *BJU Int* 2011;108:798-805; discussion 805.
35. Brunckhorst O, Aydin A, Abboudi H, Sahai A, Khan MS, Dasgupta P, et al. Simulation-based ureteroscopy training: a systematic review. *J Surg Educ* 2015;72:135-43.
36. Aghamir SMK, Salavati A. Endovisually guided zero radiation ureteral access sheath placement during ureterorenoscopy. *Minim Invasive Ther Allied Technol* 2018;27:143-7.
37. Karabulut I, Keskin E, Bedir F, Yilmazel FK, Ziyapak T, Doluoglu OG, et al. Rigid ureteroscope aided insertion of ureteral access sheath in retrograde intrarenal surgery. *Urology* 2016;91:222-5.
38. Clayman RV, Castaneda-Zuniga WR, Hunter DW, Miller RP, Lange PH, Amplatz K. Rapid balloon dilatation of the nephrostomy track for nephrostolithotomy. *Radiology* 1983;147:884-5.
39. Ekman P, Husain I, Sharma ND, Al-Faqih SR. Transurethral ureteroscopy. Safety guide wire as an aid to a more aggressive approach. *Br J Urol* 1987;60:23-7.
40. Patel SR, McLaren ID, Nakada SY. The ureteroscope as a safety wire for ureteronephroscopy. *J Endourol* 2012;26:351-4.
41. Dickstein RJ, Kreshover JE, Babayan RK, Wang DS. Is a safety wire necessary during routine flexible ureteroscopy? *J Endourol* 2010;24:1589-92.
42. Türk C, Neisius A, Petrik A, Seitz C, Skolarikos A, Thomas K, et al. EAU guidelines on urolithiasis: disease management, ureteroscopy [Internet]. Arnheim: European Association of Urology; 2020 Mar [cited 2020 Nov 1]. Available from: <https://uroweb.org/guideline/urolithiasis/#3-4>.
43. Takayasu H, Aso Y. Recent development for pyeloureteroscopy: guide tube method for its introduction into the ureter. *J Urol* 1974;112:176-8.
44. Yong C, Knudsen BE. Ureteroscopy: accessory devices. In: Humphreys MR. *Ureteroscopy for stone disease*. Torino: Minerva Medica; 2016;55-70.
45. Traxer O, Thomas A. Prospective evaluation and classification of ureteral wall injuries resulting from insertion of a ureteral access sheath during retrograde intrarenal surgery. *J Urol* 2013;189:580-4.
46. Rehman J, Monga M, Landman J, Lee DI, Felfela T, Conradie MC, et al. Characterization of intrapelvic pressure during ureteropyeloscopy with ureteral access sheaths. *Urology* 2003;61:713-8.
47. Auge BK, Pietrow PK, Lallas CD, Raj GV, Santa-Cruz RW, Preminger GM. Ureteral access sheath provides protection against elevated renal pressures during routine flexible ureteroscopic stone manipulation. *J Endourol* 2004;18:33-6.
48. Sener TE, Cloutier J, Villa L, Marson F, Butticiè S, Doizi S, et al. Can we provide low intrarenal pressures with good irrigation flow by decreasing the size of ureteral access sheaths? *J Endourol* 2016;30:49-55.
49. Yoshida T, Inoue T, Abe T, Matsuda T. Evaluation of intrapelvic pressure when using small-sized ureteral access sheaths of $\leq 10/12$ F in an ex vivo porcine kidney model. *J Endourol* 2018;32:1142-7.
50. Lyon ES, Huffman JL, Bagley DH. Ureteroscopy and ureteropyeloscopy. *Urology* 1984;23(5 Spec No):29-36.
51. Blew BD, Dagnone AJ, Pace KT, Honey RJ. Comparison of Peditrol irrigation device and common methods of irrigation. *J Endourol* 2005;19:562-5.
52. Inoue T, Yamamichi F, Okada S, Hamamoto S, Fujisawa M; SMART Study Group. Change in irrigation flow through a flexible ureteroscope with various devices in the working channel: comparison between an automatic irrigation pump and gravity-based irrigation. *Int J Urol* 2020;27:333-8.
53. Lama DJ, Owyong M, Parkhomenko E, Patel RM, Landman J, Clayman RV. Fluid dynamic analysis of hand-pump infuser and UROMAT Endoscopic Automatic System for Irrigation through a flexible ureteroscope. *J Endourol* 2018;32:431-6.
54. Denstedt JD, Razvi HA, Sales JL, Eberwein PM. Preliminary experience with holmium: YAG laser lithotripsy. *J Endourol* 1995;9:255-8.
55. Sourial MW, Knudsen BE. Ho:YAG laser lithotripsy. In: Schwartz BF, Denstedt JD. *Ureteroscopy: a comprehensive contemporary guide*. Cham: Springer; 2020;101-12.
56. Wollin DA, Ackerman A, Yang C, Chen T, Simmons WN, Preminger GM, et al. Variable pulse duration from a new holmium:YAG laser: the effect on stone comminution, fiber tip degradation, and repulsion in a dusting model. *Urology* 2017;103:47-51.

57. Kronenberg P, Somani B. Advances in lasers for the treatment of stones-a systematic review. *Curr Urol Rep* 2018;19:45.
58. Keller EX, De Coninck V, Doizi S, Daudon M, Traxer O. What is the exact definition of stone dust? An in vitro evaluation. *World J Urol* 2020 Apr 8 [Epub]. <https://doi.org/10.1007/s00345-020-03178-z>.
59. Dauw CA, Simeon L, Alruwaily AF, Sanguedolce F, Hollingsworth JM, Roberts WW, et al. Contemporary practice patterns of flexible ureteroscopy for treating renal stones: results of a worldwide survey. *J Endourol* 2015;29:1221-30.
60. Humphreys MR, Shah OD, Monga M, Chang YH, Krambeck AE, Sur RL, et al. Dusting versus basketing during ureteroscopy-which technique is more efficacious? A prospective multicenter trial from the EDGE research consortium. *J Urol* 2018;199:1272-6.
61. El-Nahas AR, Almousawi S, Alqattan Y, Alqadri IM, Al-Shaiji TF, Al-Terki A. Dusting versus fragmentation for renal stones during flexible ureteroscopy. *Arab J Urol* 2019;17:138-42.
62. Elhilali MM, Badaan S, Ibrahim A, Andonian S. Use of the Moses technology to improve holmium laser lithotripsy outcomes: a preclinical study. *J Endourol* 2017;31:598-604.
63. Keller EX, de Coninck V, Audouin M, Doizi S, Bazin D, Daudon M, et al. Fragments and dust after Holmium laser lithotripsy with or without "Moses technology": how are they different? *J Biophotonics* 2019;12:e201800227.
64. Ibrahim A, Elhilali MM, Fahmy N, Carrier S, Andonian S. Double-blinded prospective randomized clinical trial comparing regular and Moses modes of holmium laser lithotripsy. *J Endourol* 2020;34:624-8.
65. Liang H, Liang L, Yu Y, Huang B, Chen J, Wang C, et al. Thermal effect of holmium laser during ureteroscopic lithotripsy. *BMC Urol* 2020;20:69.
66. Traxer O, Keller EX. Thulium fiber laser: the new player for kidney stone treatment? A comparison with Holmium:YAG laser. *World J Urol* 2020;38:1883-94.
67. Andreeva V, Vinarov A, Yaroslavsky I, Kovalenko A, Vyborov A, Rapoport L, et al. Preclinical comparison of superpulse thulium fiber laser and a holmium:YAG laser for lithotripsy. *World J Urol* 2020;38:497-503.
68. Cetti RJ, Biers S, Keoghane SR. The difficult ureter: what is the incidence of pre-stenting? *Ann R Coll Surg Engl* 2011;93:31-3.
69. Viers BR, Viers LD, Hull NC, Hanson TJ, Mehta RA, Bergstralh EJ, et al. The difficult ureter: clinical and radiographic characteristics associated with upper urinary tract access at the time of ureteroscopic stone treatment. *Urology* 2015;86:878-84.
70. Haleblan G, Kijvikai K, de la Rosette J, Preminger G. Ureteral stenting and urinary stone management: a systematic review. *J Urol* 2008;179:424-30.
71. Cevik I, Dillioglugil O, Akdas A, Siegel Y. Is stent placement necessary after uncomplicated ureteroscopy for removal of impacted ureteral stones? *J Endourol* 2010;24:1263-7.
72. Byrne RR, Auge BK, Kourambas J, Munver R, Delvecchio F, Preminger GM. Routine ureteral stenting is not necessary after ureteroscopy and ureteropyeloscopy: a randomized trial. *J Endourol* 2002;16:9-13.
73. Pukkala E, Kesminiene A, Poliakov S, Ryzhov A, Drozdovitch V, Kovgan L, et al. Breast cancer in Belarus and Ukraine after the Chernobyl accident. *Int J Cancer* 2006;119:651-8.
74. United States Nuclear Regulatory Commission. Section 20.1201-occupational dose limits for adults, subpart C-occupational dose limits, part 20-Standards for Protection Against Radiation, Chapter I-Nuclear Regulatory Commission, NRC Regulations Title 10 of the Code of Federal Regulations [Internet]. Rockville (MD): United States Nuclear Regulatory Commission; 1991 [cited 2020 Nov 1]. Available from: <https://www.nrc.gov/reading-rm/doc-collections/cfr/part020/part020-1201.html>.
75. Durán A, Hian SK, Miller DL, Le Heron J, Padovani R, Vano E. Recommendations for occupational radiation protection in interventional cardiology. *Catheter Cardiovasc Interv* 2013;82:29-42.
76. Institute of Physics and Engineering in Medicine. Medical and dental guidance notes: a good practice guide on all aspects of ionising radiation protection in the clinical environment. York: Institute of Physics and Engineering in Medicine; 2002.
77. Fernström I, Johansson B. Percutaneous pyelolithotomy. A new extraction technique. *Scand J Urol Nephrol* 1976;10:257-9.
78. Hellawell GO, Mutch SJ, Thevendran G, Wells E, Morgan RJ. Radiation exposure and the urologist: what are the risks? *J Urol* 2005;174:948-52; discussion 952.
79. Kumari G, Kumar P, Wadhwa P, Aron M, Gupta NP, Dogra PN. Radiation exposure to the patient and operating room personnel during percutaneous nephrolithotomy. *Int Urol Nephrol* 2006;38:207-10.
80. Majidpour HS. Risk of radiation exposure during PCNL. *Urol J* 2010;7:87-9.
81. Elkoushy MA, Shahrour W, Andonian S. Pulsed fluoroscopy in ureteroscopy and percutaneous nephrolithotomy. *Urology* 2012;79:1230-5.
82. Kokorowski PJ, Chow JS, Strauss KJ, Pennison M, Tan W, Cilento B, et al. Prospective systematic intervention to reduce patient exposure to radiation during pediatric ureteroscopy. *J Urol* 2013;190(4 Suppl):1474-8.
83. Inoue T, Komemushi A, Murota T, Yoshida T, Taguchi M, Kinoshita H, et al. Effect of protective lead curtains on scattered radiation exposure to the operator during ureteroscopy for stone disease: a controlled trial. *Urology* 2017;109:60-6.

84. Borges CE, Reggio E, Vicentini FC, Reis LO, Carnelli GR, Fregonesi A. How are we protecting ourselves from radiation exposure? A nationwide survey. *Int Urol Nephrol* 2015;47:271-4.
85. Zewu Z, Hequn C, Yu C, Yang L, Zhongqing Y, Zhiyong C, et al. Long-term outcome after flexible ureteroscopy with holmium laser for simultaneous treatment of a single renal cyst and ipsilateral renal stones. *J Int Med Res* 2019;47:3601-12.
86. Geavlete P, Georgescu D, Mirciulescu V, Niță G. Ureteroscopic laser approach in recurrent ureteropelvic junction stenosis. *Eur Urol* 2007;51:1542-8.
87. Inoue T, Okada S, Hamamoto S, Miura H, Matsuzaki J, Tambo M, et al. Evaluation of flexible ureteroscope with an omnidirectional bending tip, using a JOYSTICK unit (URF-Y0016): an ex-vivo study. *World J Urol* 2020 Mar 14 [Epub]. <https://doi.org/10.1007/s00345-020-03151-w>.
88. Tambo M, Inoue T, Miura H, Matsuzaki J, Nutahara K, Hamamoto S, et al. A novel flexible ureteroscope with omnidirectional bending tip using joystick-type control unit (URF-Y0016): initial validation study in bench models. *J Endourol* 2020;34:676-81.
89. Zhu Z, Cui Y, Zeng F, Li Y, Chen Z, Hequn C. Comparison of suctioning and traditional ureteral access sheath during flexible ureteroscopy in the treatment of renal stones. *World J Urol* 2019;37:921-9.
90. Proietti S. New technology in retrograde intrarenal surgery: unnecessary luxury vs. measurable benefit [abstract]. 35th Annual European Association of Urology Congress; 2020 Jul 17-19. Arnhem: European Association Urology; 2020.
91. Inoue T, Okada S, Hamamoto S, Matsuda T. New advanced bench model for flexible ureteroscopic training: the Smart Simulator. *J Endourol* 2018;32:22-7.
92. Sağlam R, Muslumanoglu AY, Tokath Z, Çaşkurlu T, Sarica K, Taşçı Aİ, et al. A new robot for flexible ureteroscopy: development and early clinical results (IDEAL stage 1-2b). *Eur Urol* 2014;66:1092-100.
93. Desai MM, Grover R, Aron M, Ganpule A, Joshi SS, Desai MR, et al. Robotic flexible ureteroscopy for renal calculi: initial clinical experience. *J Urol* 2011;186:563-8.
94. Geavlete P, Sağlam R, Georgescu D, Muțescu R, Iordache V, Kabakci AS, et al. Robotic flexible ureteroscopy versus classic flexible ureteroscopy in renal stones: the initial Romanian experience. *Chirurgia (Bucur)* 2016;111:326-9.
95. Brodie A, Vasdev N. The future of robotic surgery. *Ann R Coll Surg Engl* 2018;100(Suppl 7):4-13.